

# Pneumatic Displacement Performed for A Large Submacular Hemorrhage in Polypoidal Choroidal Vasculopathy

Dian Mayangsari<sup>1</sup> and Muhammad Firmansjah<sup>2</sup>

## Abstract

*Submacular hemorrhage (SMH) is defined as blood in the area between the neurosensory retina and the retinal pigment epithelium (RPE). The etiology that is frequently brought on by intraocular tumors, trauma, myopic choroidal neovascularization, macro-aneurysm, polypoidal choroidal vasculopathy (PCV), and neovascular age-related macular degeneration (AMD). A significant submacular bleeding is a typical PCV symptom. This case report is to report a submacular hemorrhage case which are managed with pneumatic displacement. A 65-year-old man complaining of a sudden decrease in central vision. An evaluation of the fundus revealed a bleeding. The hemorrhage was 4-disc diameters on the largest meridian. The patient was performed pneumatic displacement. PCV presents with multiple, recurrent serosanguineous RPE detachments. Experts favor the timely displacement of subretinal blood from the macula because they believe that therapy timing is critical in the resolution of SMH. The functional prognosis is good, and it is linked to abrupt sight loss.*

**Keywords:** *Intravitreal Gas Injection, Pneumatic Displacement, Polypoidal Choroidal Vasculopathy, Submacular Hemorrhage.*

## INTRODUCTION

Blood that is present between the neurosensory retina and the retinal pigment epithelium (RPE) at the macular area due to choroidal and retinal vascular abnormalities is referred to as submacular hemorrhage (SMH) (Kunavisarut et al., 2018). A medical condition known as submacular hemorrhage (SMH) is frequently brought on by intraocular tumors, trauma, myopic choroidal neovascularization, macro-aneurysm, neovascular age-related macular degeneration (AMD) and polypoidal choroidal vasculopathy (PCV) (Bardak et al., 2018; Kunavisarut et al., 2018).

Initially identified as bleeding syndrome in the posterior uvea, polypoidal choroidal vasculopathy (PCV) is thought to be a form of neovascular AMD that presents as Type 1 neovascularization. However, PCV type accounts for <5% of CNV3 instances in Whites, but PCV type accounts for 20%–50% of neovascular AMD cases in Asians (Abdelkader et al., 2016). An important submacular hemorrhage is a common indication of PCV. Evidence suggests that PCV is associated with a rather high incidence rate of submacular hemorrhage (30 to 63.7%) (Kitagawa et al., 2016).

As early as 24 hours after commencement, photoreceptors and submacular hemorrhage have the potential to irreparably damage the retinal pigment epithelium (RPE). This comes from the real bleeding leading to retinal damage, which contaminates the photoreceptors due to iron-based toxicity brought on by reactive oxygen radicals. The physical barrier effect of bleeding obstructing the visual axis and fibrin-based tractional forces are two other well-known reasons of the visual impairment (Heriot, 1997; Isizaki et al., 2016). If treatment is not received, SMH usually leads to poor vision in the end. Furthermore, the blood layer blocks the passage of nutrients to and from the photoreceptors, retinal pigment epithelium (RPE), and choroid by acting as a diffusion barrier (Djatikusumo et al., 2023, Lienderi et al., 2012).

As of right now, there is no traditional treatment for SMH related to PCV. Numerous treatment options for superficial macular hole (SMH) have been reported. These include the following: pneumatic displacement (PD) with or without IV tissue plasminogen activator (tPA), intravitreal (IV) anti-vascular endothelial growth factor (VEGF) agent, pars plana vitrectomy (PPV) with tPA-assisted PD, gas, IV injection of tPA, and anti-VEGF

<sup>1</sup> Department of Ophthalmology, Faculty of Medicine, Universitas Airlangga / Dr. Soetomo General Academic Hospital, Surabaya, Indonesia, +6282136981172, E-mail: dian.mayangsari-2019@fk.unair.ac.id

<sup>2</sup> Department of Ophthalmology, Faculty of Medicine, Universitas Airlangga / Dr. Soetomo General Academic Hospital, Surabaya, Indonesia

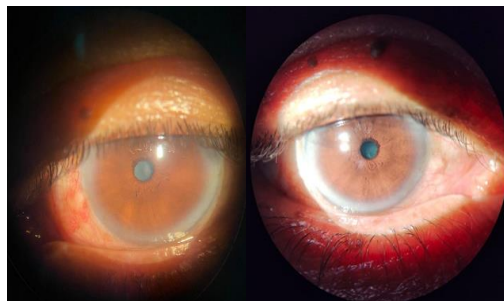
agent; surgical removal of hematoma, with or without removal of the choroidal neovascular membrane (CNVM), and subretinal tPA and an anti-VEGF agent (de Jong et al., 2016; Hykin, 2015).

One method of managing bleeding behind the macula is pneumatic displacement, which involves injecting gas. The main benefit of this technique is that blood is moved from the macula, which is located beneath the retina, to other parts of the retina that are not as important for vision. This is not an attempt to halt the bleeding; rather, it is meant to keep the macula from suffering irreversible damage from the blood below (Chang et al., 2014; McCannel et al., 2014). The objective of this case report is to provide a case of submacular hemorrhage treated with pneumatic displacement.

### Case Illustration

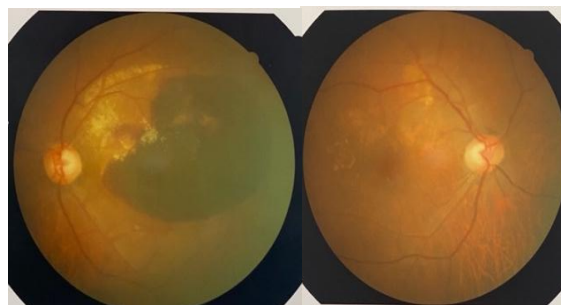
A man 65 years of age was referred to the Vitreoretinal division in Soetomo General Hospital, Surabaya, reporting that after waking up, his left eye's central vision had suddenly decreased, estimated as less than seven days before. He complaining of seeing a black shadow in his central vision. There was no history of wearing eyeglasses in both eyes. Past medical history of trauma is denied, history of diabetes mellitus is denied, history of hypertension is denied, history of frequent bleeding is denied before. Physical examination of generalist status are general conditions: good, blood pressure: 130/70 mmHg, pulse: 84x/minute, temperature: 36,5°C, respiration: 18x/minute.

The intraocular pressure was 11 mm Hg and the best corrected visual acuity in the left eye was one meter counting fingers at the ophthalmological examination. In the right eye, the visual acuity was 0.30 LogMAR corrected +1.00D became 0.00 LogMAR, the intra ocular pressure was 14 mmHg. An examination of the anterior segment in both eyes showed a deep anterior chamber, iris radier, pupil isocoria in 3 mm diameter, and pupillary reflex both eyes were normal, and the lens in both eyes were opaque (Figure 1). Extra-ocular motions were normal in both eyes.



**Figure 1.** Anterior segment in both eyes show immature cataract.

On the posterior segment examination, a large hemorrhage was found at the submacular in the left eye. The hemorrhage was 4-disc diameters on the largest meridian. a large submacular hemorrhage was documented through fundus imaging (Figure 2). the fundus examination in the right eye was normal.

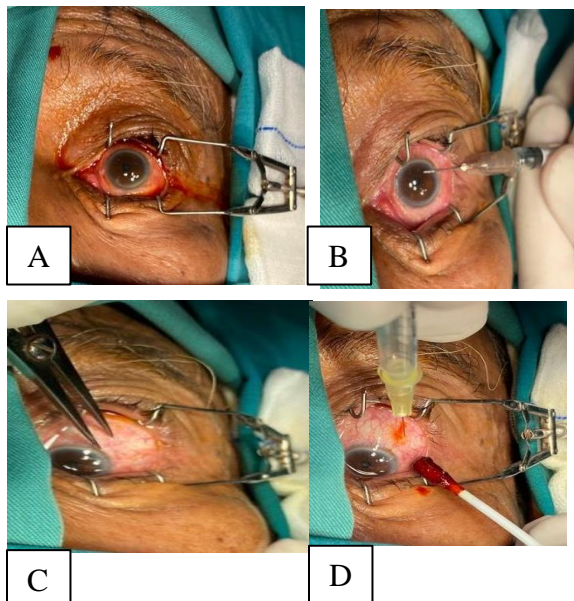


**Figure 2.** During the fundus examination, a significant hemorrhage in the left eye was discovered.

Examination with optical coherence tomography (OCT) can reveal the macula layer, subretinal fluid, subretinal blood, and assess retinal pigment epithelium (Regillo et al., 2011). The typical symptom of PCV, as shown by the scanning of the left eye, was a massive submacular hemorrhage and a dome-like elevation of RPE with considerable internal reflectivity. (Figure 3). Management is informed consent, hospitalized, pro pneumatic displacement, pro x-ray thorax PA, blood check. The choice of therapy in this patient is carried out by Pneumatic Displacement by injecting SF<sub>6</sub> gas (Figure 4). The bulbar conjunctiva was cleaned and prepared using povidone-iodine to ensure aseptic conditions (Arun et al., 2015).

To keep the intraocular pressure stable, parasentesis of the anterior chamber was performed. Using a 30-gauge needle inserted intravitreally 4mm from the limbus in phakic eyes, 0.4 ml of 100% sulfur hexafluoride (SF<sub>6</sub>) gas was administered. Expansile gas (SF<sub>6</sub>) was injected into the vitreous cavity. After surgery, the patient was advised to stay in a prone position for at least seven days.

The next six-day, patient said an improvement on his central vision. From the examination of best corrected visual acuity in the left eye was two meters counting finger and intraocular pressure was 13 mm Hg. The fundus examination and the OCT examination on the left eye show a decreased in submacular hemorrhage (Figure 5). Then, this patient is planned to treat with serial antiVGEF injection to improve the condition.



**Figure 4.** Pneumatic Displacement by injecting SF<sub>6</sub> gas. 4A. Povidone-iodine was used to clean and prepare the bulbar conjunctiva. 4B parasentesis of the anterior chamber was performed. 4C. 4mm from the limbus in phakic eye. 4D. gas was injected intravitreally.

## DISCUSSION

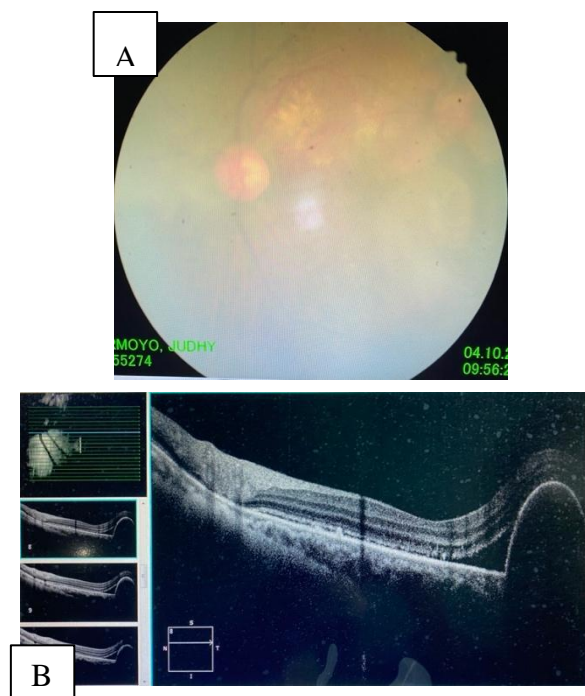
We report a case of pneumatic displacement and expansile gas (SF<sub>6</sub>) injection for extensive submacular hemorrhage. The 65-year-old patient complained of a sharp decline in his left eye's central vision after waking up, which he estimated to have occurred fewer than seven days prior, and was referred to the Vitreoretina section of Soetomo General Hospital, Surabaya. He said that he could see a black shadow in the center of his eyesight. blurry vision without experiencing any discomfort, absence of red eyes, perception of a flash of light, absence of a flying item, and perception as though there were no curtains.

One common sign of PCV is an SMH. Unexpected sight loss is associated to SMH caused by PCV. Serosanguineous RPE detachments are multiple and recurrent in PCV presentations. Feeder arteries attached to the fibrovascular PED's RPE monolayer in a "string-of-pearls" pattern are linked to a network of polyps (Chang et al., 2018; Kunavisarut et al., 2018). The macula layer, subretinal fluid, subretinal blood, and RPE assessment may all be seen in this patient using an optical coherence tomography (OCT) examination. A

significant submacular hemorrhage and a dome-like elevation of RPE with substantial internal reflectivity were observed during the left eye's scanning, which is indicative of PCV (Fassbender et al., 2016).

Polyp identification can be aided by the use of OCTA, SD-OCT, and indocyanine green angiography (ICGA). Branching vascular network with aneurysmal dilations, commonly referred to as polyps, is seen in ICGA. Submacular hemorrhage is known to occur with a very high incidence rate (30 to 63.7%) in cases with PCV (Hirashima et al., 2015; Shin et al., 2015).

During the posterior segment examination, a significant bleeding at the left eye's submacular area was discovered. On the largest meridian, the bleeding was four disc diameters in size. A rare but severe side effect of choroidal neovascularization is a massive submacular hemorrhage (SMH) (Shin et al., 2015). Pneumatic displacement was carried out on the patient via intravitreal gas injection. This method's primary advantage is that it transfers blood from the macula beneath the retina to other, less vision-critical regions of the retina. The goal of this procedure is to protect the macula from long-term harm caused by the blood beneath, not to stop the bleeding. In cases of submacular bleeding (Figure 5), this pneumatic displacement approach offers a straightforward, efficient, and minimally invasive treatment (Kim et al., 2018).



**Figure 5.** Evaluation after six days post pneumatic displacement. 5A. Hemorrhage in the macula is decreased seen through fundus examination 5B. OCT in the left eye show polypoidal lesions as seen as inverted-U-shaped elevations of the RPE, but the hemorrhage seems resolved.

In this case, a week after the symptoms started, the PD was completed. Pneumatic displacement should ideally be completed in 7–14 days to reduce irreversible vision loss brought on by submacular hemorrhage. The prognosis for vision declines with the duration of hemorrhage in the subretinal space (Bae et al., 2016; Kim et al., 2015). According to research on animals, bleeding in the subretinal region causes significant harm to the outer nuclear layer and photoreceptors within 24 hours, as well as additional deterioration of the RPE and photoreceptors after seven days (Baek et al., 2018; Ying et al., 2016).

Three primary mechanisms underlie the harm that persistent SMH causes to photoreceptors: toxicity connected to iron, reduced oxygen and nutrient transport, and mechanical damage brought on by clot contraction. It's critical to remove SMH as soon as possible to reduce side effects and enhance the prognosis for vision. Experts support a timely displacement of subretinal blood from the macula because they believe that therapy timing is critical in resolving SMH. While older SMH have been linked to significantly worse functional outcomes, the

majority of research conducted to yet have included individuals with hemorrhages lasting less than 14 days (Abiyoga et al., 2023).

The SMH intervention employed both non-vitreotomizing and vitreotomizing techniques. Pars-plana vitrectomy (PPV) is usually carried out with intravitreal or subretinal injections of recombinant tissue-plasminogen activator (rt-PA) to dissolve clots in the blood and facilitate the removal of gas tamponade. During the surgical evacuation of SMH, the risk of proliferative vitreoretinopathy and retinal detachment is increased when PPV is used with a large retinotomy (about 310 mm). A number of case series showed significant VA improvement and successful SMH displacement using vitreotomizing techniques (Abiyoga et al., 2023). To remove the SMH from behind the fovea, nonvitreotomizing techniques use the administration of intravitreal expansile gases, either alone or in conjunction with additional adjuvants. Heriot initially provided a straightforward method for treating SMH. that involved injecting tissue plasminogen activator (t-PA) intravitreously while simultaneously using expansile gas to pneumatically remove SMH. The patient's post-operative visual acuity has improved in this case. SMH deriving from PCV typically has positive visual implications, however SMH originating from other sources has been associated with a poorer prognosis for vision (Kadonosono et al., 2015). The patient's condition is expected to improve much more with a scheduled round of anti-VEGF injections. Studies looking back have demonstrated that PD combined with IV anti-VEGF medications can successfully treat SMH in nAMD patients (Abidin et al., 2024).

The prognosis in this patient is *quo ad functionam dubia* due to extensive sub-macular hemorrhage of more than 4 disc areas. Better visual outcomes are achieved during the usual clinical course of PCV due to a lower incidence of subretinal fibrosis than AMD. The extent and duration of the submacular hemorrhage may potentially have an impact on the functional result (Kimura et al., 2015).

## **CONCLUSION**

One common indication of PCV is submacular hemorrhage. There is an abrupt loss of vision, but the functional prognosis is good. The functional outcome could be affected by the degree and length of the submacular hemorrhage. One simple, less invasive procedure that has a decreased chance of intraocular complications is pneumatic displacement. Pneumatic displacement aims to transfer blood from underneath the macula to regions of the retina that are less crucial for vision. For submacular bleeding, pneumatic displacement therapy seems to be a secure and practical method.

## **Acknowledgments**

We would like to sincerely thank M. Firmansjah, MD, our supervisor, for his invaluable advice and assistance. His knowledge and perceptions were quite helpful in forming our paper and assisting us in overcoming obstacles.

## **Conflict of Interest**

In this review article there is no potential conflict of interest.

## **Funding Source**

Not applicable.

## **Ethical Clearance**

Not applicable.

## **Authors' Contribution**

All authors contributed equally to this review article.

## REFERENCES

- Abdelkader, E., Yip, K. P., & Cornish, K. S. (2016, Oct-Dec). Pneumatic displacement of submacular haemorrhage. *Saudi J Ophthalmol*, 30(4), 221-226. <https://doi.org/10.1016/j.sjopt.2016.10.002>
- Abidin, A. Z., Ichsan, A. M., Muhiddin, H. S., & Eka, H. (2024). Pro and Anti-Inflammatory Factors in Patients with Rhegmatogenous Retinal Detachment with Silicone Oil Tamponade. *Bali Medical Journal*, 13(1), 350-355. <https://doi.org/10.15562/bmj.v13i1.5067>
- Abiyoga, K., Lutfi, D., Primitasari, Y., Maharani, C. D., Finanda, C., Sasono, W., Komaratih, E., & Legowo, J. (2023). Bevacizumab and triamcinolone acetonide intravitreal effect on Transforming Growth Factor Beta (TGF- $\beta$ ) and Plasminogen Activator Inhibitor-1 (PAI-1) expression in open globe injury model. *Bali Medical Journal*, 12(2), 1846-1854. <https://doi.org/10.15562/bmj.v12i2.4534>
- Arun, A., Sadhana, A., & Shankar, R. (2015). Correlation between structural retinal nerve fibre layer thickness and functional visual field loss in Primary open angle glaucoma. *Bali Medical Journal*, 4(1), 28-31. <https://doi.org/10.15562/bmj.v4i1.107>
- Bae, K., Cho, G. E., Yoon, J. M., & Kang, S. W. (2016). Optical Coherence Tomographic Features and Prognosis of Pneumatic Displacement for Submacular Hemorrhage. *PloS One*, 11(12), e0168474. <https://doi.org/10.1371/journal.pone.0168474>
- Baek, J., Kim, J. H., Lee, M. Y., & Lee, W. K. (2018, Oct). DISEASE ACTIVITY AFTER DEVELOPMENT OF LARGE SUBRETINAL HEMORRHAGE IN POLYPOIDAL CHOROIDDAL VASCULOPATHY. *Retina*, 38(10), 1993-2000. <https://doi.org/10.1097/iae.0000000000001817>
- Bardak, H., Bardak, Y., Erçalık, Y., Erdem, B., Arslan, G., & Timlioglu, S. (2018, May). Sequential tissue plasminogen activator, pneumatic displacement, and anti-VEGF treatment for submacular hemorrhage. *European Journal of Ophthalmology*, 28(3), 306-310. <https://doi.org/10.5301/ejo.5001074>
- Chang, W., Garg, S. J., Maturi, R., Hsu, J., Sivalingam, A., Gupta, S. A., Regillo, C. D., & Ho, A. C. (2014, Jun). Management of thick submacular hemorrhage with subretinal tissue plasminogen activator and pneumatic displacement for age-related macular degeneration. *American Journal of Ophthalmology*, 157(6), 1250-1257. <https://doi.org/10.1016/j.ajo.2014.02.007>
- Chang, Y. S., Kim, J. H., Kim, J. W., Kim, C. G., & Lee, D. W. (2018, Oct). Development of Submacular Hemorrhage in Neovascular Age-related Macular Degeneration: Influence on Visual Prognosis in a Clinical Setting. *Korean Journal of Ophthalmology*, 32(5), 361-368. <https://doi.org/10.3341/kjo.2017.0095>
- de Jong, J. H., van Zeeburg, E. J., Cereda, M. G., van Velthoven, M. E., Faridpooya, K., Vermeer, K. A., & van Meurs, J. C. (2016, May). INTRAVITREAL VERSUS SUBRETINAL ADMINISTRATION OF RECOMBINANT TISSUE PLASMINOGEN ACTIVATOR COMBINED WITH GAS FOR ACUTE SUBMACULAR HEMORRHAGES DUE TO AGE-RELATED MACULAR DEGENERATION: An Exploratory Prospective Study. *Retina*, 36(5), 914-925. <https://doi.org/10.1097/iae.0000000000000954>
- Djatikusumo, A., Victor, A. A., Wibowo, H., Nora, R. L. D., Harahap, A. R., Setiabudy, R., Sovani, I., Ardhia, S. H., & Adishabri, A. K. (2023). Arachidonic acid pathway in proliferative vitreoretinopathy: the study of the vitreous biomarker in rhegmatogenous retinal detachment. *Bali Medical Journal*, 12(2), 2298-2302. <https://doi.org/10.15562/bmj.v12i2.4637>
- W.N. Lienderi, P. Budhiastra, A. Andayani, The Characteristic of Central Serous Chorioretinopathy Patients at Sanglah General Hospital Bali-Indonesia, *Bali Medical Journal*, 2012, 1, 82-87. <https://doi.org/10.1016/j.ajo.2014.02.007>
- Fassbender, J. M., Sherman, M. P., Barr, C. C., & Schaal, S. (2016, Oct). TISSUE PLASMINOGEN ACTIVATOR FOR SUBFOVEAL HEMORRHAGE DUE TO AGE-RELATED MACULAR DEGENERATION: Comparison of 3 Treatment Modalities. *Retina*, 36(10), 1860-1865. <https://doi.org/10.1097/iae.0000000000001030>
- Heriot, W. J. (1997). Further experience in management of submacular hemorrhage with intravitreal tPA.
- Hirashima, T., Moriya, T., Bun, T., Utsumi, T., Hirose, M., & Oh, H. (2015, Oct). OPTICAL COHERENCE TOMOGRAPHY FINDINGS AND SURGICAL OUTCOMES OF TISSUE PLASMINOGEN ACTIVATOR-ASSISTED VITRECTOMY FOR SUBMACULAR HEMORRHAGE SECONDARY TO AGE-RELATED MACULAR DEGENERATION. *Retina*, 35(10), 1969-1978. <https://doi.org/10.1097/iae.0000000000000574>
- Hykin, P. (2015). *Retinal Vein Occlusion (RVO) Guidelines*. The Royal College of Ophthalmology. London.
- Hye, Q. M.A., & Wizarat, S. (2011). Impact of financial liberalization on agricultural growth: a case study of Pakistan. *China Agricultural Economic Review*, 3(2), 191-209.
- Isizaki, E., Morishita, S., Sato, T., Fukumoto, M., Suzuki, H., Kida, T., Ueki, M., & Ikeda, T. (2016, Apr). Treatment of massive subretinal hematoma associated with age-related macular degeneration using vitrectomy with intentional giant tear. *International Ophthalmology*, 36(2), 199-206. <https://doi.org/10.1007/s10792-015-0102-6>
- Kadonosono, K., Arakawa, A., Yamane, S., Inoue, M., Yamakawa, T., Uchio, E., & Yanagi, Y. (2015, Jan). Displacement of submacular hemorrhages in age-related macular degeneration with subretinal tissue plasminogen activator and air. *Ophthalmology*, 122(1), 123-128. <https://doi.org/10.1016/j.ophtha.2014.07.027>
- Kim, J., Chang, Y., Kim, J., Lee, T., & Kim, C. (2015, 06/03). Prevalence of subtypes of reticular pseudodrusen in newly diagnosed exudative age-related macular degeneration and polypoidal choroidal vasculopathy in Korean patients. *Retina (Philadelphia, Pa.)*, 35. <https://doi.org/10.1097/IAE.0000000000000633>
- Kim, J. H., Chang, Y. S., Kim, J. W., Kim, C. G., & Lee, D. W. (2018). Early Recurrent Hemorrhage in Submacular Hemorrhage Secondary to Type 3 Neovascularization or Retinal Angiomatous Proliferation: Incidence and Influence on Visual Prognosis. *Seminars in Ophthalmology*, 33(6), 820-828. <https://doi.org/10.1080/08820538.2018.1511814>

*Pneumatic Displacement Performed for A Large Submacular Hemorrhage in Polypoidal Choroidal Vasculopathy*

- Kimura, S., Morizane, Y., Hosokawa, M., Shiode, Y., Kawata, T., Doi, S., Matoba, R., Hosogi, M., Fujiwara, A., Inoue, Y., & Shiraga, F. (2015, Apr). Submacular hemorrhage in polypoidal choroidal vasculopathy treated by vitrectomy and subretinal tissue plasminogen activator. *American Journal of Ophthalmology*, 159(4), 683-689. <https://doi.org/10.1016/j.ajo.2014.12.020>
- Kitagawa, Y., Shimada, H., Mori, R., Tanaka, K., & Yuzawa, M. (2016, Jun). Intravitreal Tissue Plasminogen Activator, Ranibizumab, and Gas Injection for Submacular Hemorrhage in Polypoidal Choroidal Vasculopathy. *Ophthalmology*, 123(6), 1278-1286. <https://doi.org/10.1016/j.ophtha.2016.01.035>
- Kunavisarut, P., Thithuan, T., Patikulsila, D., Choovuthayakorn, J., Watanachai, N., Chaikitmongkol, V., Pathanapitoon, K., & Rothova, A. (2018, Mar-Apr). Submacular Hemorrhage: Visual Outcomes and Prognostic Factors. *Asia Pac J Ophthalmol (Phila)*, 7(2), 109-113. <https://doi.org/10.22608/apo.2017389>
- McCannel, C. A., Atebara, N. H., Kim, S. J., Leonard, B. C., & Rosen, R. B. (2014). *Retina and Vitreous*. American Academy of Ophthalmology.
- Regillo, C., Holekamp, N., Johnson, M., Kaiser, P., Schubert, H., Spaide, R., Schmidt-Erfurth, U., & Bennett, P. (2011). Basic and clinical science course, section 12: Retina and vitreous. San Francisco, American Academy of Ophthalmology.
- Shin, J. Y., Lee, J.-m., & Byeon, S. H. (2015). Anti-vascular endothelial growth factor with or without pneumatic displacement for submacular hemorrhage. *American Journal of Ophthalmology*, 159(5), 904-914. e901. <https://doi.org/10.1016/j.ajo.2015.01.024>
- Ying, G. S., Maguire, M. G., Daniel, E., Grunwald, J. E., Ahmed, O., & Martin, D. F. (2016, Feb). Association between Antiplatelet or Anticoagulant Drugs and Retinal or Subretinal Hemorrhage in the Comparison of Age-Related Macular Degeneration Treatments Trials. *Ophthalmology*, 123(2), 352-360. <https://doi.org/10.1016/j.ophtha.2015.09.046>